

New Technologies in Endourology

Adjustable Continence Therapy for Treatment of Recurrent Female Urinary Incontinence

Ervin Kocjancic, M.D.,¹ Simone Crivellaro, M.D.,^{1,2} John Joseph Smith III, M.D.,²
Stefania Ranzoni, M.D.,³ Daniele Bonvini, M.D.,⁴ and Bruno Frea, Prof.¹

Abstract

Purpose: The Adjustable Continence Therapy (ACT[®]) device has been developed for the treatment of recurrent stress urinary incontinence resulting from intrinsic sphincter deficiency (ISD) by increasing urethral coaptation. We critically evaluated the technique and its results.

Methods: The ACT device consists of two balloons each attached to an injectable port placed in the labia majora. The port enables postoperative adjustment in balloon coaptation pressure. All 49 patients had previously failed anti-incontinence surgery. Each patient was implanted with the ACT device and assessed by preoperative and postoperative overall impression, incontinence quality of life questionnaire, and visual analog scale; 38 of the 49 subjects had a minimum of 1 year of data collected, including pad use, number of adjustments needed, and complications.

Results: Mean operative time was 20.3 minutes (range 10–30 minutes), with 88% of implantations performed using local or regional anesthesia. Balloon adjustments were needed in 62%; 68% of patients reported being dry and 16% improved. Complications included migration (12%), balloon failure (3.6%), and erosion (4%).

Conclusion: The ACT device provided significant improvement in at least 70% of patients with recurrent stress urinary incontinence.

Introduction and Discussion of the Technology

SURGICAL MANAGEMENT OF intractable female stress urinary incontinence can be complicated by increasing amounts of scar tissue following each intervention, and the pendulum effect that swings between incontinence and voiding dysfunction. The Adjustable Continence Therapy (ACT[®]) device is a new method for treating female stress urinary incontinence due to intrinsic sphincter deficiency (ISD). The ACT (Uromedica, Inc., Plymouth, MN) was developed to address the need for a minimally-invasive procedure that could act similarly to bulking agents, but without the migration issues intrinsic to the use of free-floating bulking agents.¹ It was also clear that an adjustable technique was needed for postoperative correction in patients who were not completely continent following surgery, and in those who de-

veloped voiding difficulties as a result of overcorrection.² The ACT consists of two silicone balloons attached via conduits to a titanium and silicone port (Fig. 1). The balloons are placed under fluoroscopic imaging in the periurethral space at the bladder neck with the aim of increasing urethral resistance and supporting the bladder neck.³ The ports are buried in the subcutaneous tissue of the labia majora and enable postoperative adjustment of the balloon should this become necessary.

The procedure is particularly useful to surgeons who are adept at endourologic procedures, as endoscopic dexterity and a thorough understanding of female pelvic anatomy are integral to the successful mastery of optimal balloon placement to help ensure improvement in continence. In principle, the ideal female patient is one who has failed primary, secondary, or even tertiary procedures, who has a modicum

¹Clinica Urologica, Azienda Ospedaliero Universitaria, Udine, Italy.

²Urology Department, Wake Forest Baptist Medical Center, Winston-Salem, North Carolina.

³Clinica Urologica, Ospedale Maggiore della Carita, Novara, Italy.

⁴Cattedra di Igiene, Dipartimento scienze mediche A. Avogadro, Novara, Italy.

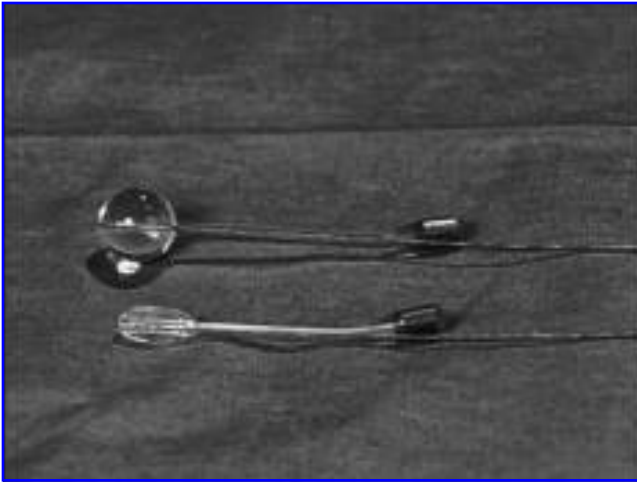


FIG. 1. ACT balloons with push wire in place.




FIG. 2. U-shaped cannula and sharp trocar.

of scar tissue that may serve to enhance the bulking effect of the balloons. These patients are usually characterized by an open bladder neck or a fixed open proximal urethra at rest, as demonstrated on the filling phase of a voiding cystourethrogram by a low Valsalva leak point pressure, and maximum urethral closure pressure at urodynamic investigation. In our series all patients had failed at least one previous surgical intervention for treatment of their stress urinary incontinence (Table 1), and they all had normal detrusor function. We excluded patients with grade II or greater uncorrected pelvic organ prolapse, associated bladder disorders, urethral stricture, or detrusor sphincter dysynergia.

Prior to balloon implantation, a detailed continence and obstetric history was taken from all patients, and all underwent a standard physical examination, urodynamic testing, and cystoscopy. Pad usage was noted and patients were asked to complete an incontinence quality-of-life questionnaire (IQOL)⁴ and had visual analogue scale (VAS) scoring at baseline and at 1, 3, 6, and 12 months postoperatively, and annually thereafter. Moreover, complications and the number of adjustments were recorded at each time point.

The Surgical Procedure

With the patient in standard lithotomy position, the bladder was filled with 150 mL of dilute contrast medium

through an 18F Foley catheter that was inserted with 10 mL of concentrated contrast medium to make the bladder neck visible. Bilateral 1-cm incisions were made in the labial sulcus at the level of the vaginal introitus below the urethral meatus. Using fluoroscopic guidance and digital vaginal palpation, a sharp trocar encased in a U-shaped cannula was directed through the incision, perforating the pelvic floor towards the bladder neck (Figs. 2 and 3). A rotating action employing the blade mechanism on the distal tip of the trocar is used to advance the instrument, while simultaneously using gentle traction on the Foley catheter to locate the bladder neck (Fig. 4). Accurate localization of the trocar is assisted by digital palpation against the anterior vaginal wall. Following perforation of the pelvic floor, a blunt trocar may be employed if there is a risk of urethral or bladder perforation. Once the tip of the trocar is at the bladder neck, the trocar is removed and the incremental markers are used to measure the correct device length by retracting the inner trocar while maintaining the U-shaped cannula in position. When the tip of the trocar reaches the labial skin edge, the

TABLE 1. PREVIOUS ANTI-INCONTINENCE PROCEDURES

Procedures	No. of patients
TVT	10
TOT	8
BURCH	8
Bulking agents	30
MMK	5
Artificial sphincter	1

BURCH = Burch Colposuspension; MMK = Marshall Marchetti Kranz; TOT = transobturator tape; TVT = transvaginal tape.

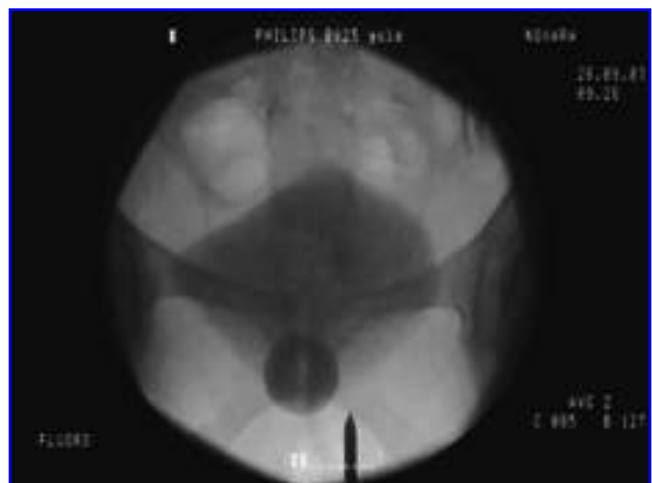

FIG. 3. Image showing the tip of the trocar directed towards the bladder neck.

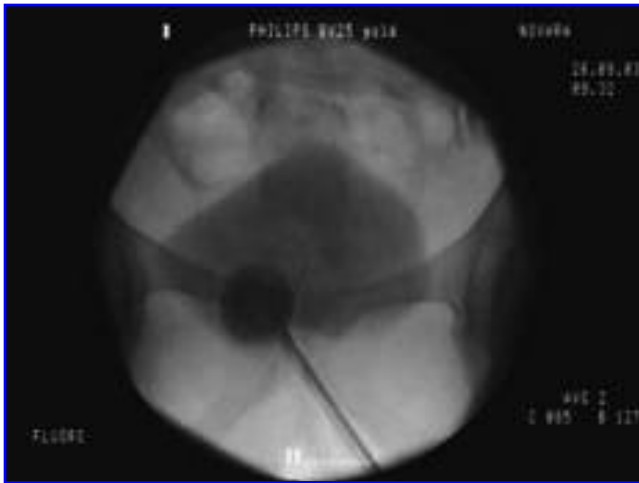

FIG. 4. Image showing trocar and Foley catheter balloon manipulation.

proper device length can be determined by counting the corresponding incremental markings at the distal portion of the trocar. The trocar is then fully removed leaving the cannula in place. The sterile balloon is then primed to remove air and ensure patency. The devices are soaked in antibiotic solution before insertion. The balloon is then lubricated and advanced through the U-shaped cannula to the bladder neck using the removable guidewire as a pusher. Care is taken to avoid undermining the bladder neck and placing the balloon under the bladder trigone, as this could result in *de novo* urgency. In the event that a bladder or urethral perforation has occurred, urine will be seen flowing down the U-shaped cannula and leakage of contrast solution from the bladder will be seen on fluoroscopy. Following a bladder perforation the instrumentation should be removed and a new tract created. Placement of the balloon on the side of a urethral perforation should be postponed for 6 weeks to allow healing and to avoid the possibility of fistula formation. The balloon is inserted into the U-shaped cannula using a pre-loaded guidewire as a pusher (Fig. 5). The balloon is filled with 1 to 1.5 mL of an isotonic solution (sterile water and contrast

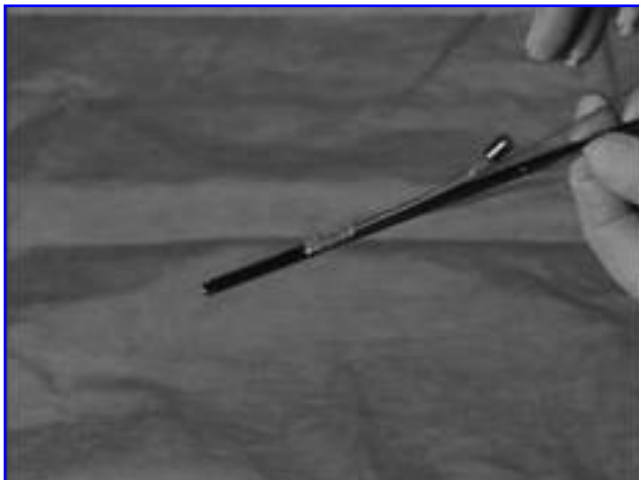


FIG. 5. ACT balloon directed down the U-shaped cannula.

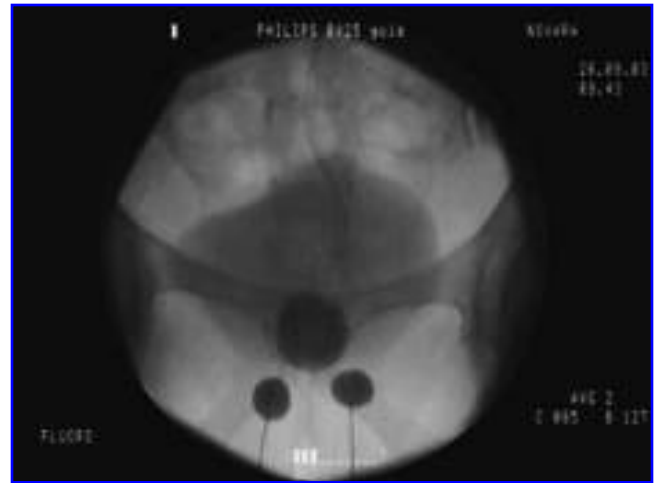


FIG. 6. Image showing balloons in final position.

medium) to stabilize its position, and the process is repeated on the contralateral side. The correct position is confirmed on the image intensification screen, and this image should be saved for future reference (Fig. 6). The guidewire and cannula are removed, and the ports are buried in the labia majora in an easily accessible subcutaneous pouch and the incision is closed in two layers (Fig. 7). The urethral catheter remains *in situ* overnight (Fig. 8). Patients are prescribed a prophylactic single perioperative dose of gentamicin 160 mg and a postoperative course of oral ciprofloxacin 500 mg once daily for 5 days. First adjustments should not be conducted before 4 to 6 weeks to allow for pseudo-encapsulation to mature and subsequent increments should be spaced a minimum of 4 weeks apart. While incremental adjustments normally are conducted within the first 6 months, adjustments can be performed at any time.⁵

Results

Forty-nine patients were implanted with 38 providing a minimum of 1 year of follow-up data; 23 patients have been

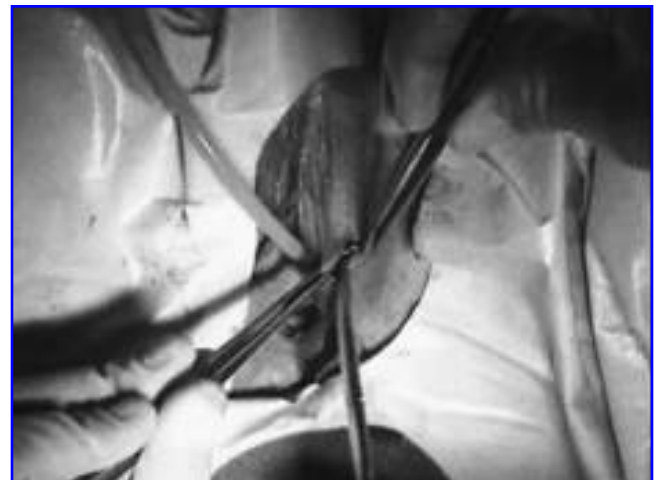

FIG. 7. Creation of the labial pocket.

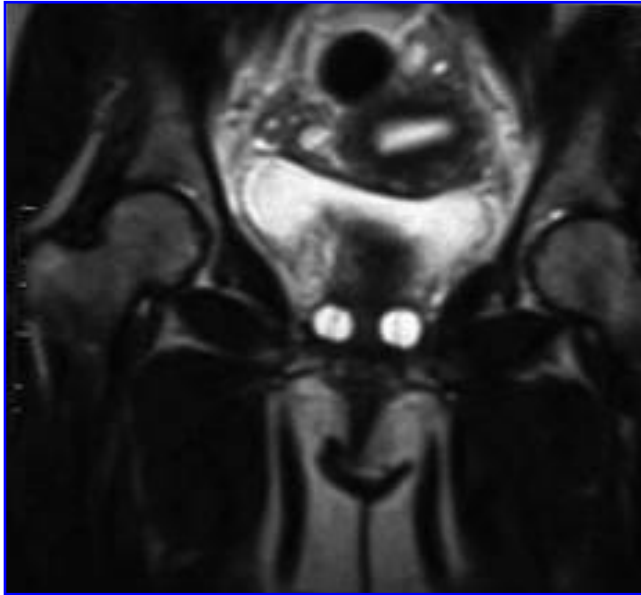


FIG. 8. MRI showing ACT balloons in place with Foley catheter.

followed for more than 4 years with a mean follow-up of 40.1 months.

Operative time was 20.3 minutes (range 10–30 minutes) with a blood loss of <50 mL in all cases. Fifteen (30.6%) of 49 patients underwent implantation utilizing local anesthesia comprising of 10 mL per side of 4% bupivacaine and 1% lidocaine; 28/49 (57%) required spinal anesthesia while 6/49 (12%) underwent general anesthesia. Mean irradiation time for verification of balloon positioning using image intensification was 2.03 minutes (range 1–3.6 minutes). Seven (14.2%) patients required 6-cm devices, 7 patients (14.2%) required 7-cm devices, 24 (48.9%) required 8-cm devices, and 11 patients (32.4%) required 9-cm devices. Intraoperatively, two bladder perforations occurred, which were made visible by leakage of contrast medium through the trocar. On each occasion the trocar was removed, repositioned via more lateral access, and balloons were inserted. In these two patients, the urethral catheter was retained for 48 hours. No further postoperative sequelae resulted. All other patients were able to void within 24 hours with no post-void residual assessed on ultrasound. No postoperative analgesia was required and all patients were discharged within 24 hours of surgery.

We considered all 49 patients in our assessment of complications, erosions, and explants. However, we report only on the 38 patients with at least 12 months of follow-up when

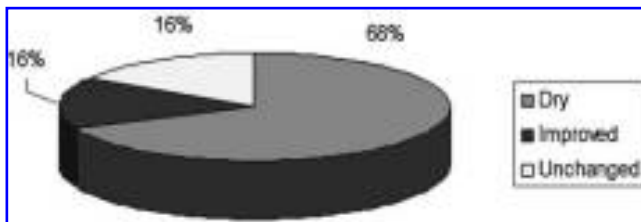


FIG. 9. Graph depicting breakdown of patient overall impression of the ACT device.

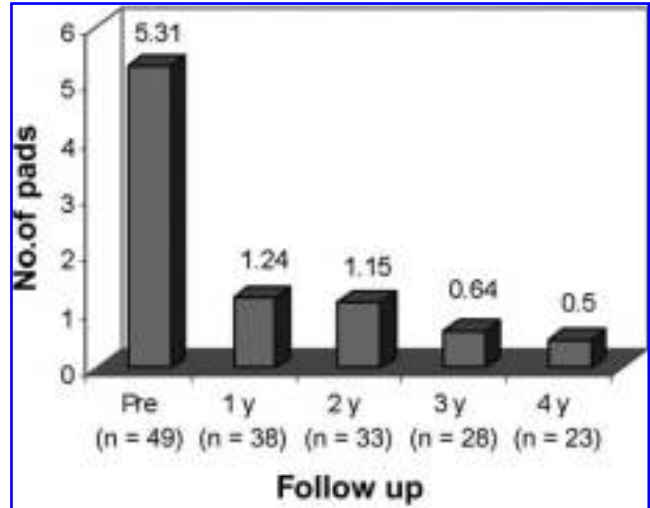


FIG. 10. Graph depicting pad usage pre- and postoperatively.

reporting efficacy. In doing so, 26/38 patients (68%) reported being dry, 6/38 (16%) improved, and 6/38 (16%) remained unchanged at last follow-up (Fig. 9).

Postoperatively there was significant improvement in both pad usage and IQOL over time as seen in Figures 10 and 11. Additionally, patients reported significant improvement in symptoms based on their VAS scores.

In our series, 38% of patients did not require any postoperative adjustments, with the remaining 62% requiring between one and five adjustments over the duration of their follow-up period.

Complications included six migrations (12%) and two urethral or portal erosions (4%) necessitating device removal and subsequent replacement. Three balloons (6%) failed in the early postoperative period and were easily explanted and replaced. All the 11 patients who required removal and replacement have at least 12 months of follow-up, and therefore are included in the results; 70% of them were dry after reimplantation and an additional 10% were improved.

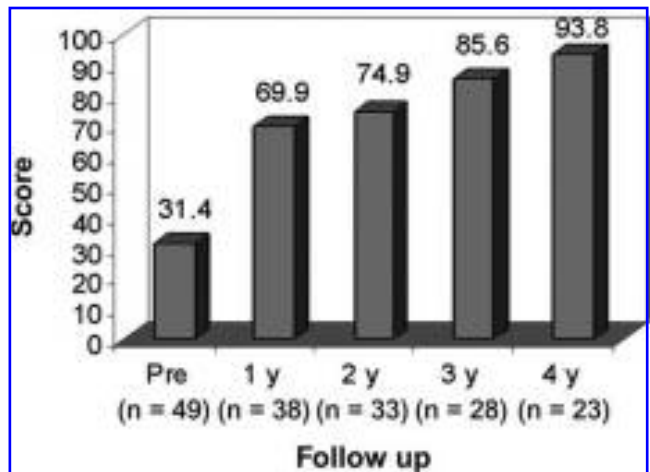


FIG. 11. Graph depicting IQOL questionnaire scores pre- and postoperatively.

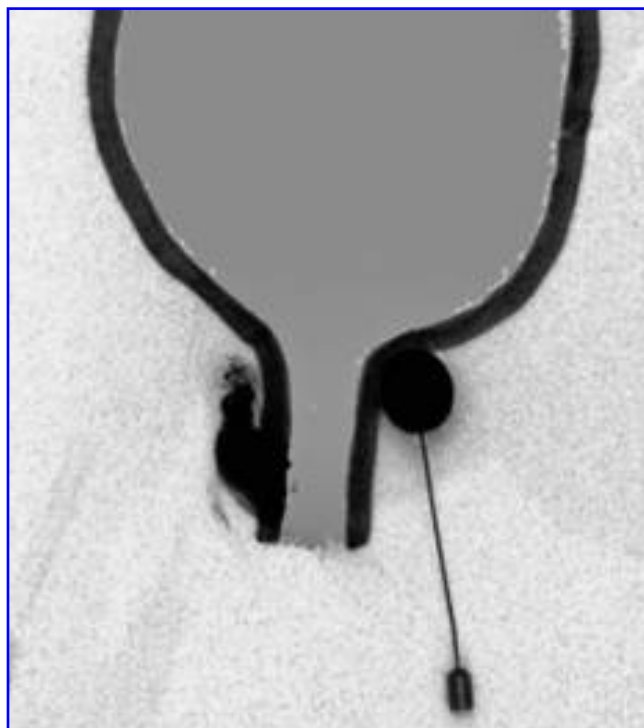


FIG. 12. Migrated bulking agent in paraurethral space on the right and contained bulking agent in ACT device on the left.

Discussion

The concept of using injectables to increase urethral resistance is well established.⁶ Two of the known complications of injectables are the difficulty in ensuring accurate placement of the material,⁷ and the lack of prolonged maintenance of effect (Fig. 12).⁸ Possible operative complications relating to the ACT include bladder or urethral perforation. Bladder perforations are easily managed by the creation of a new tract and extended postoperative catheterization of 3 to 5 days. In the case of a urethral perforation, balloon implantation on the affected side should be postponed for 6 to 8 weeks. Potential postoperative complications are primarily balloon migration, urethral erosion, and infection. Migration may be related to poor surgical technique or to previous anti-incontinence surgery. We observed that positioning of the ACT device is more challenging in the presence of a mid-urethral tension-free tape placed either with a retropubic or trans-obturator approach than following injection of bulking agents or open suspension procedures. Where a tape remains *in situ*, the ACT device should be placed cranially to the tape. Erosion secondary to infection can be limited by the judicious use of antibiotics peri-operatively, and recognition of the importance of utilizing aseptic technique during implantation and any subsequent adjustments. To date no late infections have occurred, a pattern similar to that seen with other urologic prostheses. In our experience, port erosion can be dramatically reduced by providing greater tissue coverage of the buried ports. Postoperative complications in our series were minor and were easily treated by device removal, which can be performed in an outpatient setting.

Unlike many other surgical techniques that demonstrate a high short-term success that decreases over time,⁹ results

of ACT placement appear to improve over time. During the first 12 months at least 68% of patients considered themselves dry, and this effect appears to plateau or remain stable. This may be a result of the ability to adjust the pressure balloon.

Conclusion

The ACT device provided significant improvement in at least 70% of patients with recurrent stress urinary incontinence. We thus conclude that the ACT device and technique provide good outcomes in a difficult group of patients.

References

1. Stewart CS, Jones BJ, Lightner DJ. Post procedural adjustable peri-urethral bulking device. Urodynamic evaluation of efficacy in a canine model. AUA North Central Region, Scottsdale, AZ, November 2000.
2. Debodinance P, Delport P, Engrand JB, Boulogne M. Complications of urinary incontinence surgery: 800 procedures. *J Gynecol Obstet Biol Reprod (Paris)* 2002;31:649–662.
3. Stecco A, Saponaro A, Crivellaro S, Cotroneo AR, Frea B, Kocjancic E. Can MRI predict which patients are most likely to benefit from percutaneous positioning of volume adjustable balloon devices? *Urologia Internationalis* 2006;76:240–246.
4. Wagner TH, Patrick DL, Bavendam T, Martin M, Buesching D. Quality of life of people with urinary incontinence: Development of a new measure. *Urology* 1996;1:67–72.
5. Hubner WA, Schlarp OM. Treatment of incontinence after prostatectomy using a new minimally invasive device: Adjustable continence therapy. *BJU Int* 2005;96:587–594.
6. Stenzl A, Strasser H. Submucosal bladder neck injections for the management of stress urinary incontinence. *Braz J Urol* 2000;26:199–207.
7. Pannek J, Brands FH, Senge T. Particle migration after transurethral injection of carbon coated beads for stress urinary incontinence. *J Urol* 2001;166:1350–1353.
8. Maher CF, O'Reilly BA, Dwyer PL, Carey MP, Cornish A, Schuller P. Pubovaginal sling versus transurethral Macroplastique for urinary incontinence and intrinsic sphincter deficiency: A randomised controlled trial. *BJOG* 2005;112:797–801.
9. Koelbl H, Saz V, Doerfler D, Haeusler G, Sam C, Hanzal E. Transurethral injection of silicone microimplants for intrinsic urethral sphincter deficiency. *Obstet Gynecol* 1998;92:332–336.

Address reprint requests to:
Ervin Kocjancic, M.D.

Clinica Urologica
Azienda Ospedaliero Universitaria di Udine
P.zza S. Maria della Mesericordia 15
33100 Udine, Italy

E-mail: crivellaro76@hotmail.com

Abbreviations Used

ACT = Adjustable Continence Therapy
IQOL = incontinence quality-of-life (questionnaire)
ISD = intrinsic sphincter deficiency
VAS = visual analogue scale.

